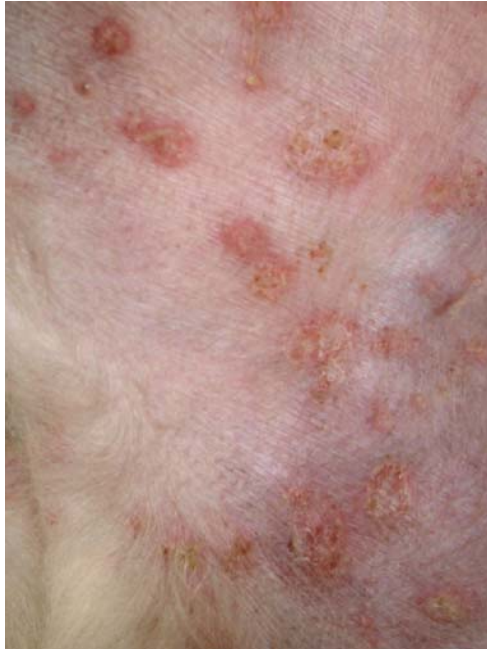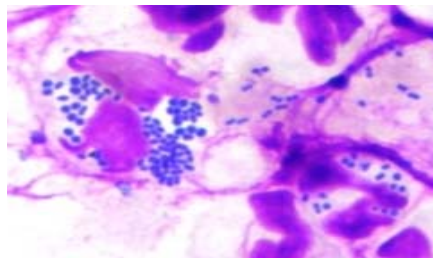

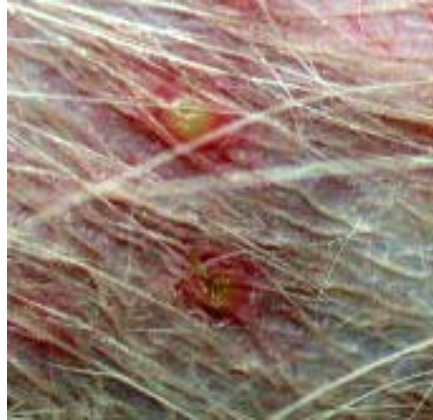
The Practical Dermatology Team Lesion Atlas

Primary Lesions

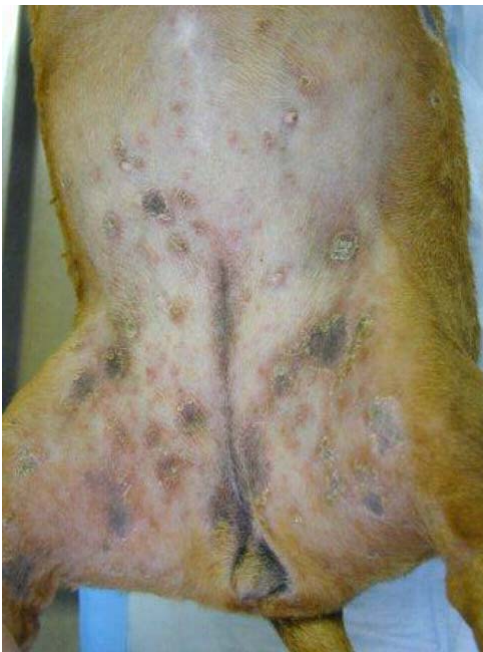

Papule

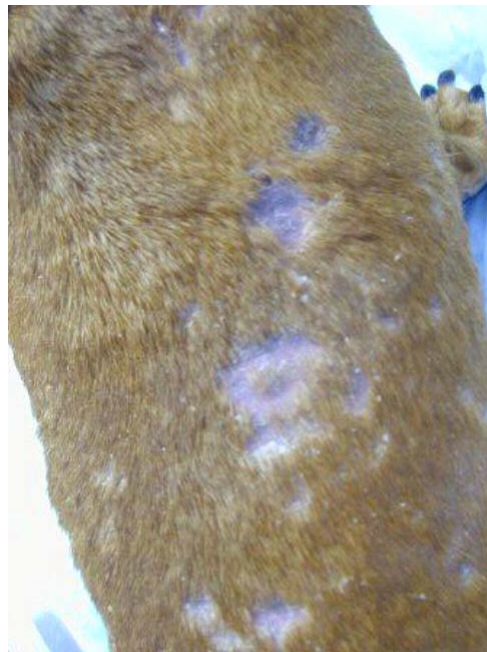


Pustule

Secondary Lesions:

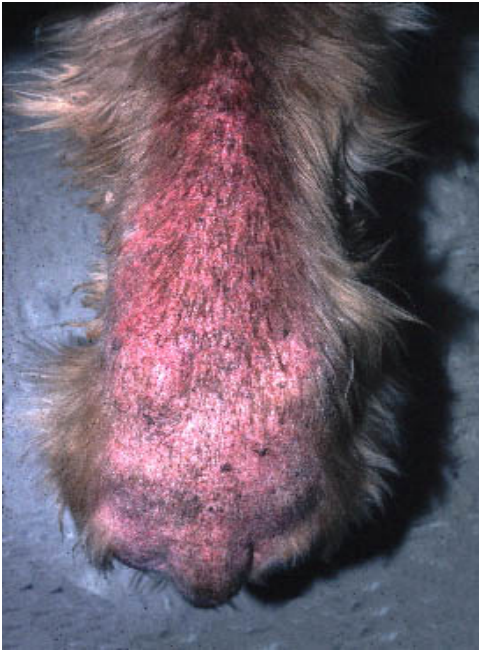

Epidermal collarettes

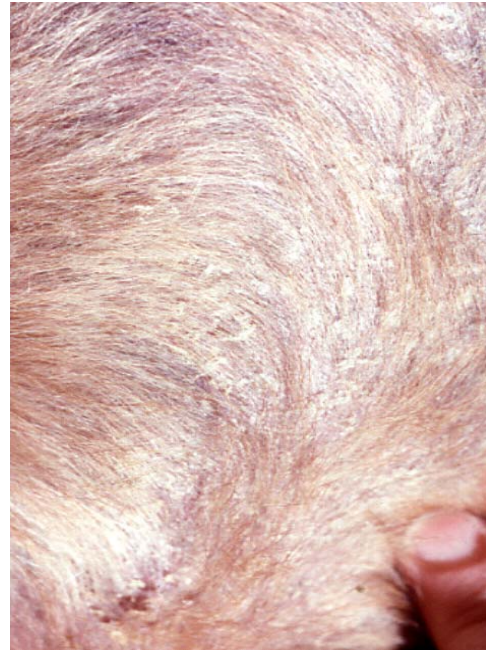


Alopecia

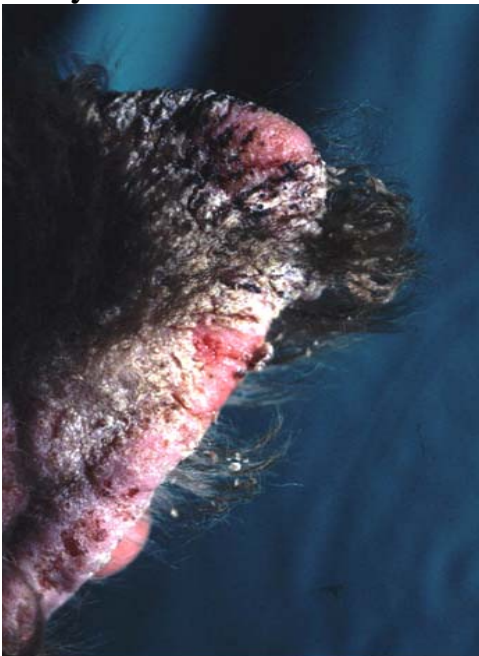Secondary Lesions



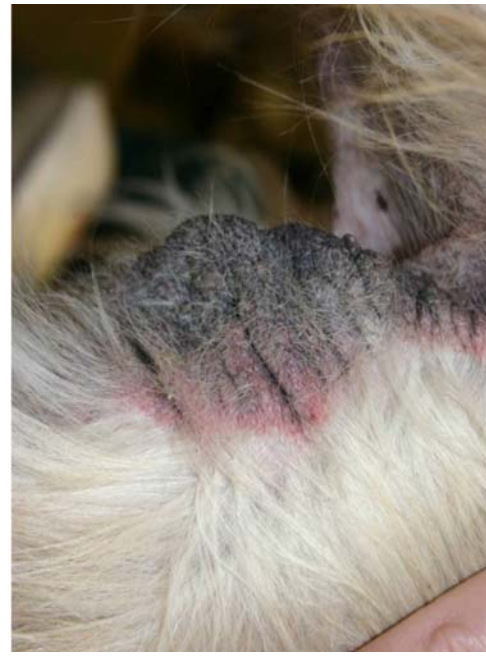Erythema



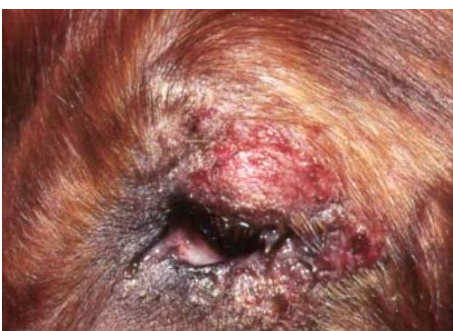Scale



Crust



Hyperpigmentation / Lichenification



Excoriation